

# Screw “Tent-Pole” Grafting Technique for Reconstruction of Large Vertical Alveolar Ridge Defects Using Human Mineralized Allograft for Implant Site Preparation

*Bach Le, DDS, MD,\* Michael D. Robrer, DDS, MS,† and  
Hari S. Prasad, BS, MDT‡*

**Purpose:** The purpose of this study was to evaluate the effectiveness of using titanium screws in combination with particulate human mineralized allograft, in a “tenting” fashion, to augment large vertical alveolar ridge defects for implant placement.

**Materials and Methods:** This prospective case study evaluated augmentation in consecutive patients with large (>7 mm) vertical alveolar ridge defects. Vertical ridge augmentation was performed using mineralized allograft placed around titanium screws to tent out the soft tissue matrix. The ridges were clinically evaluated 4 to 5 months after augmentation, and implants were placed at that time. Bone cores were harvested from all patients for histologic evaluations.

**Results:** Fifteen patients were treated in this prospective case study, and the mean vertical augmentation was 9.7 mm. Two patients had wound dehiscence resulting in loss of graft and requiring secondary grafting before implant placement. Five patients required 2-stage grafting procedures to achieve ideal ridge height before implant placement. Clinical evaluation of the grafted sites upon re-entry revealed uniform ridge anatomy. Histomorphometric analysis of 7 specimens revealed a mean bone content of 43%. A total of 32 implants were placed into grafted sites in 15 patients. All implants were integrated and successfully restored. Mean follow-up was 16.8 months after implant placement.

**Conclusions:** Tenting of the periosteum and soft tissue matrix with titanium screws maintains space and minimizes resorption of mineralized particulate allograft. This technique offers predictable functional and esthetic reconstruction of large vertical defects without the use of autogenous bone and is capable of osseointegration. More studies are needed to evaluate the stability of vertically grafted bone after long-term loading.

© 2010 American Association of Oral and Maxillofacial Surgeons  
*J Oral Maxillofac Surg* 68:428-435, 2010

Bone augmentation grafting of large vertical maxillary and mandibular alveolar ridge defects is difficult. Various techniques have been described for the reconstruction of these large vertical defects before implant placement. These techniques have included autogenous onlay block grafts,<sup>1-4</sup> autogenous particulate grafts,<sup>5-8</sup> distraction osteogenesis,<sup>9</sup> and porous titanium mesh tray,<sup>10,11</sup> or a combination of these.<sup>12-14</sup> Marx et al<sup>15</sup> reported on a novel surgical approach

using dental implants as “tent poles” in combination with iliac crest bone grafting in the successful treatment of 64 severely resorbed mandibles, resulting in a mean bone height gain of 10.2 mm. The novel strategy of this surgery was to allow iliac bone grafts to consolidate and maintain their volume with dental implants that create a tenting effect.

Augmentation with titanium mesh can also be successful but has a high exposure rate of the mesh and

\*Clinical Associate Professor, Department of Oral and Maxillofacial Surgery, USC School of Dentistry, Los Angeles, CA.

†Director, Hard Tissue Research Laboratory, University of Minnesota, School of Dentistry, Minneapolis, MN.

‡Research scientist, Hard Tissue Research Laboratory, University of Minnesota, School of Dentistry, Minneapolis, MN.

The authors have no financial interests in any of the products mentioned in this article.

Address correspondence and reprint requests to Dr Le: Oral & Maxillofacial Surgery, USC School of Dentistry, 925 West 34th Street, Los Angeles, CA 90089; e-mail: leb97201@yahoo.com

© 2010 American Association of Oral and Maxillofacial Surgeons

0278-2391/10/6802-0030\$36.00/0

doi:10.1016/j.joms.2009.04.059

subsequent partial graft loss. Louis et al<sup>10</sup> recently reported on 44 patients who had undergone titanium mesh reconstruction of the maxilla or mandible using iliac crest bone graft with a 52.27% exposure rate of the titanium mesh. Although these authors reported a 97% overall graft success rate with this technique, exposure of autogenous grafts to the oral environment inevitably leads to unpredictable loss of graft volume, and it is unclear how this partial loss affected the overall treatment plan.<sup>10</sup> Distraction osteogenesis can be successful in vertical augmentation, but in our experience, it often leaves undesirable tissue scarring and usually requires secondary bone augmentation before implants can be placed.

Block and Degen reported on the use of particulate human mineralized allograft alone to successfully augment partially edentulous segments for implant placement through a minimally invasive tunneling technique.<sup>16</sup> However, apical migration of graft material from the alveolar crest tends to occur with this "closed" technique. This is likely due to natural tissue contraction because of the inability to maintain passive space. In addition, direct visualization and correction of the defect, especially in the esthetic areas, can be challenging with this tunneling technique. Le et al and Le and Burstein described using human particulate mineralized allograft as a particulate onlay graft to correct small volume hard tissue defects and in combination with cortical ramus block grafts as a tenting mechanism in an open approach to treat the severely resorbed alveolar ridge before implant placement.<sup>17,18</sup>

A major challenge to reconstructing large vertical bone defects is the contraction of the "soft tissue matrix" leading to resorption and migration of the bone graft. Surgical control of the expanded soft tissue volume prevents resorption of graft material<sup>15</sup> by maintaining a space between the periosteum and bone.

Alveolar ridge augmentation using autogenous block grafts is a predictable method to augment localized alveolar ridge defects but can be difficult in large 3-dimensional defects (Figs 1A-C). Furthermore, these large atrophic segments present a more challenging scenario in reconstruction, as there is a limited supply of intraoral donor bone. Extraoral donor sites are an option but present an obstacle to patient treatment acceptability because of increased costs and morbidity.

The purpose of this case study was to evaluate the effectiveness of using particulate human mineralized allograft, in combination with titanium screws, in a "tenting" fashion to augment large, localized, intraoral, vertical alveolar ridge defects for implant placement. This concept would make it possible to graft large, 3-dimensional, vertical segments without the need to

harvest autogenous bone from extraoral or intraoral sites. The hypothesis for this case study was whether 1.5-mm screws in combination with human mineralized bone could be used as an osteoconductive scaffold to restore large vertical defects resulting in sufficient bone quantity and quality after 4 to 5 months to allow for subsequent osseointegration of endosseous implants.

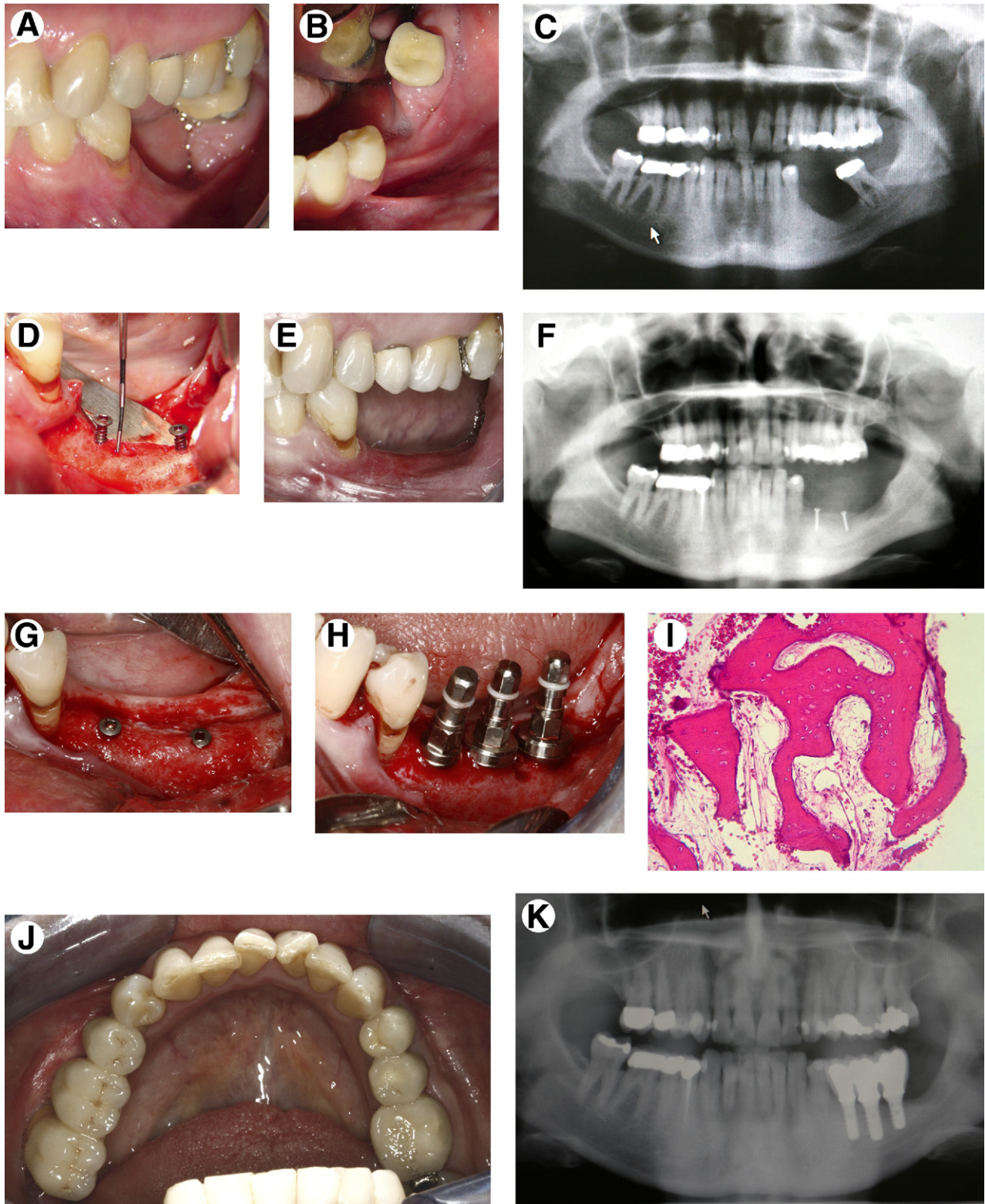
## Materials and Methods

This prospective case study evaluated augmentation in 15 consecutive patients presenting with large vertical alveolar ridge defect. Inclusion criteria for this study were partially edentulous patients seeking dental implant therapy who required more than 7 mm of vertical alveolar ridge augmentation before implant placement. Patients selected for this procedure also must have less than 4 mm of bone width as determined by preoperative examination and CT imaging studies. Before augmentation, all grafted sites were deemed inadequate because of anatomical constraints for placement of an implant of at least 10 mm in length. Smokers, diabetic patients, and any medically compromised patients were excluded from this series. After prosthodontic consultation for implant restorations, patients were scheduled for bone grafting procedures.

Vertical ridge augmentation was performed using human mineralized allograft (Puros; Zimmer Dental, Carlsbad, CA) placed around titanium screws to tent out the soft tissue matrix and periosteum. The ridges were clinically evaluated 4 to 5 months after augmentation. Panorex radiographs and computed tomography (CT) scans were taken to evaluate all grafted segments. Bone cores were taken using a trephine of all grafted segments at the time of implant placement for histologic evaluation. Preoperative and postoperative clinical and radiographic comparisons were made at the time of implant placement. Panorex and periapical radiographs were taken after all implants were restored at follow-up intervals of 6 and 12 months.

### SURGICAL TECHNIQUE

A preoperative chlorhexidine rinse was given for 2 minutes. Surgical treatment was performed under intravenous anesthesia, and 2% lidocaine with 1:100,000 epinephrine was given as blocks and infiltrations in the maxilla and mandible. A crestal incision was made in all cases with vertical releases. Whenever possible, available keratinized tissue was identified and included in the incision design. Aggressive tissue releases were performed before screw or graft placement to ensure tension-free closure. In the anterior maxilla, subperiosteal dissection was carried up to the



**FIGURE 1.** A-C, Large 3-dimensional defect of the posterior alveolar ridge after traumatic extraction and chronic infection. Note the loss of bone attachment to the mandibular molar. D, Titanium screws placed show that 5 mm of screw threads are exposed above the ridge defect. E-G, Clinical situation after 2 grafting procedures with screw tent-pole grafting technique using mineralized allograft. H, Dental implants placed into grafted bone. Bone core is taken next to implant site for histologic analysis. I, Histologic analysis demonstrates good bone formation in grafted specimen. J, K, Final restoration at 15-month follow-up shows stable bone under functional load.

*Le, Robrer, and Prasad. Screw "Tent-Pole" Grafting for Alveolar Ridge Defects. J Oral Maxillofac Surg 2010.*



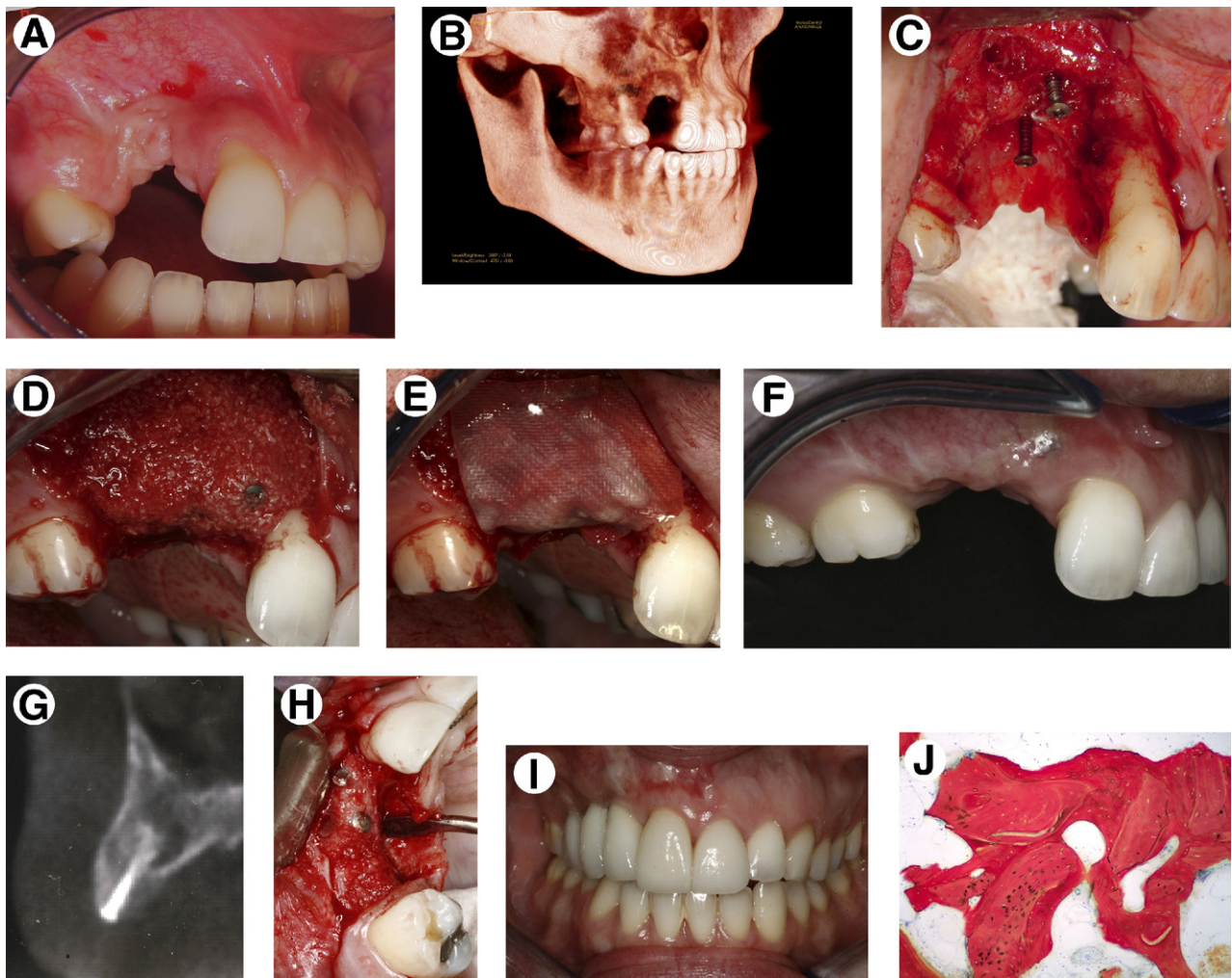
anterior nasal spine to obtain adequate release for passive primary closure. In the posterior mandible, this often involved split thickness dissection on the labial for supraperiosteal advancement.

Titanium screws (1.5 mm, KLS Martin, Jacksonville, FL) were placed in the alveolar ridge so that approximately 5 to 7 mm of screw threads were exposed (Figs 1D, 2C). Particulate mineralized allograft (cancellous particles, 250 to 1,000  $\mu\text{m}$ ) was mixed with the patient's blood and placed to cover the screw completely (Fig 2D). The defect was overcorrected with particulate material in anticipation of future graft resorption. A resorbable membrane (OSSIX PLUS; OraPharma, Warminster, PA) was placed over the

grafted sites (Fig 2E). Passive primary closure over the entire graft was obtained with interrupted 4 to 0 resorbable chromic gut sutures.

Postoperatively, the patient prosthesis was adjusted to avoid impingement on the grafted site and, when possible, to create positive tissue architecture (Fig 2F). All patients were placed on postoperative antibiotic treatment consisting of penicillin 500 mg  $\times$  7 days (for penicillin-allergic patients, clindamycin 300 mg  $\times$  7 days) and a chlorhexidine mouth rinse for 1 week. After 4 to 5 months, the grafted sites were uncovered (Figs 1G, 2H) and the screws removed.

Pre- and postoperative defects were evaluated at both the bony and soft tissue levels. Additional allo-



**FIGURE 2.** A, B, Large vertical alveolar defect resulting from failed orthodontic extrusion of impacted canine. Note the recession defect on the distal of the maxillary left central incisor and resulting open bite resulting from lack of alveolar growth. C, Titanium screws are strategically placed to tent the tissue volume. D, Human mineralized allograft (cancellous particles) placed to cover the screw heads completely. E, A long-lasting resorbable membrane is placed over the grafted site. F-H, Clinical situation 5 months after graft procedure demonstrates excellent 3-dimensional hard tissue and soft tissue reconstruction of vertical defect, with complete coverage of screw heads with newly formed bone. I, Final restorations on implants. J, Histomorphometric analysis demonstrates good bone integrity with trabeculae of uniform size and good connectivity. New bone formation is quite robust surrounding particles of mineralized allograft. The lighter-stained particles are the particles of mineralized allograft (surrounded by the darker, red staining, newly formed bone).

graft material was added at the time of implant placement to improve the final bone and soft tissue contours as necessary to affect esthetic outcome. No autogenous bone was used in this prospective case study.

## Results

Fifteen (2 male/13 female) consecutive patients with severe localized vertical alveolar ridge defects underwent surgery (Table 1). The mean patient age was 50.06 years (range 22 to 69 yrs). Six patients had grafts placed to the mandible and nine patients had grafts to augment the partially edentulous maxilla. Of the 15 patients, 12 patients had 2 or more missing teeth with severe vertical defects of the maxillary alveolar ridge. Teeth adjacent to alveolar defects with significant root exposure resulting from loss of bone attachment were extracted. Twelve patients underwent extractions of adjacent teeth to allow a more favorable bone attachment to which to graft. Adequate tension-free closure over the graft was achieved in all patients.

There were no postoperative wound infections. One patient had complete dehiscence of the grafted site with graft and screw exposure requiring subsequent graft. Although there was complete exposure of the graft material, partial graft take was noted upon re-entry after 4 months. Two patients had partial wound dehiscence and 3 patients had screw head exposure only. Wound dehiscence and screw head exposures were treated with conservative care with oral hygiene maintenance and oral rinse during the 4-month healing period. Partial graft loss was noted on re-entry in

4 patients with wound complete or partial wound dehiscence. Two of these 4 patients required a second graft procedure using the same protocols with screws. In 11 patients, complete coverage of the screw head by bone was noted. All screws were removed, and ridge width was clinically evaluated to be larger than 6 mm at all sites of implant placement.

A total of 32 implants were placed into the grafted ridges at locations predetermined by the restoring dentists preoperatively with a surgical stent. Several different implant systems were used: 6 BioHorizons implants (BioHorizons, Inc, Birmingham, AL), 15 Straumann implants (Straumann, Basel, Switzerland), 7 AstraTech implants (AstraTech, Inc, Waltham, MA), and 4 Zimmer implants (Zimmer Dental, Carlsbad, CA). Sixteen implants were placed in the maxilla and 16 were placed in the mandible. A single-staged protocol was used to place 27 implants. Only 5 implants required uncovering. All implants were allowed a waiting period of at least 3 months before the restoration phase. After 3 to 4 months of integration, all implants were noted to be integrated. All implants have been successfully restored in the 15 patients with a mean follow-up of 16.8 months (range, 4 to 38 mo) from placement. Follow-up examinations have indicated stable and healthy peri-implant tissue and bone levels.

Bone cores were harvested from all patients for histologic evaluations. In addition, 7 of the grafted specimens underwent histomorphometric analysis. All cores showed good integrity with a good cancellous bone pattern and good connectivity of the trabeculae. The new bone formation had surrounded the mineralized allograft particles and had

**Table 1. CHARACTERISTICS OF STUDY PATIENTS**

Patient No.	Gender	Age (yrs)	Implant Site	Average Follow-up
1	F	55	Mand L second molar, first molar, second bicuspid	13 mo
2	F	24	Max R cuspid, lateral incisor	5 mo
3	F	57	Mand L first molar and second bicuspid, L first molar	6 mo
4	F	48	Mand L first molar	12 mo
5	F	45	Max L lateral incisor	36 mo
6	F	57	Max R second molar, first molar, second bicuspid	9 mo
7	F	48	Mand R second bicuspid, first molar	16 mo
8	M	54	Max R lateral incisor, L lateral incisor	6 mo
9	F	63	Max L first bicuspid, first molar	30 mo
10	F	44	Max R cuspid, lateral incisor	11 mo
11	F	66	Mand L second molar, first molar	22 mo
12	F	22	Max L lateral incisor	4 mo
13	F	60	Mand R second bicuspid, first molar, second molar	16 mo
14	F	39	Max R central incisor, L lateral incisor	28 mo
15	M	69	Mand L second molar, first molar, second bicuspid	38 mo
Mean		50.06		16.8 mo

Abbreviations: Mand, mandibular; Max, maxillary, L, left; R, right.

Le, Robrer, and Prasad. Screw "Tent-Pole" Grafting for Alveolar Ridge Defects. *J Oral Maxillofac Surg* 2010.

formed bridges resulting in a good cancellous bone pattern. High-power images showed excellent integration of new bone formation and particles of mineralized allograft (Fig 2J). All grafted sites consisted of viable bone. Histomorphometric analysis of the 7 specimens revealed a mean bone content of 43%. Of this percent bone, the mean vital bone content was 81%.

## Discussion

Severe vertical alveolar ridge defects are usually 3-dimensional and present a difficult challenge to the implant surgeon. Patients with vertical defects usually have concomitant horizontal defects, and these defects must be fully reconstructed in all dimensions to create an esthetic and functional result. Furthermore, many vertical defects usually have loss of bone attachment to the teeth adjacent to the defect. In many instances, it is more beneficial to extract these teeth so that a healthy bone attachment level can be attained to which to graft bone.

Autogenous bone graft has long been considered the gold standard for grafting severe hard tissue defects. However, reconstruction of large vertical defects often requires a significant amount of autogenous bone, including extraoral sources. Louis et al<sup>10</sup> reported on the use of titanium mesh for reconstruction of severely atrophic maxilla or mandible using iliac crest bone graft with a 97% overall graft success rate, although exposure of the titanium mesh was reported to be high (52%). The obstacles to using iliac crest bone are obvious. In addition to the higher resorption rate of iliac crest grafts, other disadvantages include the high costs of hospitalization, risk of general anesthesia, and morbidity of the procedure.<sup>1,3,8,19</sup>

Conversely, the use of mineralized allograft offers many advantages, including an unlimited amount of donor bone and reduced anesthesia and operative time.<sup>16,20</sup> The procedure can be performed ideally as outpatient surgery, thereby decreasing the overall costs of the procedure. Le and Burstein reported the successful use of mineralized allograft for the reconstruction of 10 consecutive patients with severely atrophic maxilla for implant placement.<sup>18</sup> Le et al reported on using mineralized allograft as a particulate onlay graft to augment atrophic alveolar ridge for single implant site development.<sup>17</sup>

The decision to use cancellous bone versus cortical bone was anecdotal and was based on the authors' experience of seeing better incorporation and bridging of the graft material in previous histologic evaluation and upon clinical re-entry after grafting extraction socket defects. Based on the first author's experience, smaller particle size mineral-

ized allograft material also appeared to achieve quicker incorporation and bridging. Marx reported that the ideal size for capillary bud penetration is 250  $\mu\text{m}$ .<sup>21</sup> Large cortical size particles may make it more difficult to become incorporated into the graft and could theoretically act as sequestra, thereby jeopardizing the integrity of the graft.

In this series of patients, all implants (100%) placed into vertically augmented sites integrated.

By appropriately placing titanium screws interposed by particulate graft, it is possible to augment large vertical ridge defects with no need for autogenous bone. This technique involves expanding the soft tissue volume and using screws as "screw tent poles" for the surrounding particulate graft. This helps prevent the soft tissues from contracting around the particulate graft and subsequently displacing it or causing physiologic resorption.<sup>15</sup> This soft tissue maintenance concept was confirmed by the clinical observation that the particulate bone graft material resorbed no further than the level of the screw heads (Figs 1G, 2H). Although longer follow-up is needed to evaluate whether this is a permanent result, our mean follow-up of 16.8 months (range, 4 to 38 mo) demonstrates that the bone height appears to be stable. Radiographs taken at follow-up reveal crestal bone stability without any evidence of peri-implant attachment loss or inflammation with implants under functional load.

In addition to restoring the hard tissue defect, the particulate bone preserves and augments the soft tissue architecture that was lost to years of resorption. This allows an option for implant placement and creates a better esthetic result. Soft tissue contour typically follows underlying bony architecture. Any ridge augmentation through bone grafting must provide the foundation to reconstruct the hard tissue defects to affect the soft tissue architecture.

Postoperative wound infection was not observed in this patient series. Wound dehiscence occurred in 4 patients, resulting in partial loss of graft material. All 4 patients had large spans consisting of at least 2 or more missing teeth. In 1 patient with a large vertical defect (15 mm) who was missing 2 teeth, an attempt was made to correct this defect in 1 surgical procedure. In retrospect, this could have resulted in dehiscence. Although a large dehiscence of the wound occurred with exposure of the screw, membrane, and graft material in this patient, complete granulation occurred over the grafted site after removal of the exposed screw. Upon re-entry to this site for a second graft, partial graft take of the exposed site was noted. This suggests the biocompatibility of mineralized allograft and its user-friendly status in the face of graft exposure. Had this graft been autogenous bone, com-



plete loss of graft material would be expected with no possibility of partial graft take.

Four patients had large vertical defects (>10 mm) with a single missing tooth span and had successful correction of defect in a 1-stage grafting protocol. This finding suggests that large single missing tooth span may be corrected in a 1-stage surgery protocol. Four patients who developed wound dehiscence all had large span defects. This finding suggests that large spans (2 or more missing teeth) have a higher risk of wound dehiscence. Correction of these defects in a 2-surgery, smaller grafting protocol (5 to 6 mm per graft) may reduce the risk of graft dehiscence.

The overall success of this procedure can be attributed to the meticulous reflection of tissue flaps and a tension-free closure. This was achieved by releasing the periosteal flaps from the nasal spine in addition to scoring the periosteum in all maxillary cases. The incorporation of a vertical incision in the flap is also helpful in allowing further advancement of the flap. In the mandible, the release of the mylohyoid muscle from its attachment is critical in addition to a split-thickness flap on the labial to avoid damage to the mental nerve. The authors have found that this step is critical in avoiding wound dehiscence and subsequent graft resorption.

In addition to allowing primary tension-free wound closure, scoring of the periosteum promotes angiogenesis by creating bleeding into the graft.<sup>24</sup> Furthermore, creating adequate space for bone regeneration by surgically expanding the soft tissue matrix with tenting screws can help prevent resorption of the graft material.<sup>24</sup> The authors believe that the use of a resorbable membrane is important to the success of using particulate allograft. It is unclear whether the use of a membrane reduces or prevents graft resorption. Based on a systematic review of the literature, further evidence is needed to determine whether barrier membranes prevent bone resorption in autologous onlay bone grafts.<sup>22</sup> Controlled clinical trials have shown improved survival of implants when a membrane was used to cover sinus window for sinus augmentation through a lateral window approach.<sup>23,25-27</sup> The increase in implant survival may be explained by the reported higher percentage of vital bone that results when a membrane is placed over the window. Furthermore, the use of a membrane in conjunction with particulate graft is helpful in preventing graft particles from sticking to the soft tissue flap on re-entry. This is especially true because there is aggressive undermining of the periosteum and soft tissue in all grafted sites.

In our patient series, using cancellous mineralize allograft with strategically placed titanium screws has allowed us to restore large vertical bony defects in a

predictable manner without the use of autologous bone. The success reported is likely dependent on the exclusion of smokers, diabetic patients, and medically compromised patients. Further research is needed to determine whether particle size and the use of cortical versus cancellous allograft can affect the success and predictability of this procedure. Long-term follow-up is also needed to evaluate the stability of the graft after implant loading. Our preliminary report indicates that using this technique allowed the successful reconstruction of large defects in the patients selected.

## References

1. Misch CM: Comparison of intraoral donor sites for onlay grafting prior to implant placement. *Int J Oral Maxillofac Implants* 12:767, 1997
2. Rasmusson L, Meredith N, Kahnberg KE, et al: Effects of barrier membranes on bone resorption and implant stability in onlay bone grafts. An experimental study. *Clin Oral Implants Res* 10:267, 1999
3. Proussaefs P, Lozada J, Rohrer MD: A clinical and histologic evaluation of a block onlay graft in conjunction with autogenous particulate and inorganic bovine mineral (Bio-Oss): A case report. *Int J Periodontol Restor Dent* 22:567, 2002
4. Keller EE, Tolman DE, Eckert S: Surgical-prosthetic reconstruction of advanced maxillary bone compromise with autogenous onlay block bone grafts and osseointegrated endosseous implants: A 12 year study of 32 consecutive patients. *Int J Oral Maxillofac Implants* 14:197, 1999
5. Buser D, Dula K, Belsler UC, et al: Localized ridge augmentation using guided bone regeneration. II. Surgical procedure in the mandible. *Int J Periodontics Restorative Dent* 15:10, 1995
6. Buser D, Dula K, Hirt HP, et al: Lateral ridge augmentation using autografts and barrier membranes: A clinical study with 40 partially edentulous patients. *J Oral Maxillofac Surg* 54:420, 1996
7. Buser D, Dula K, Hess D, et al: Localized ridge augmentation with autografts and barrier membranes. *Periodontol* 2000 19: 151, 1999
8. Misch CM, Misch CE: The repair of localized severe ridge defects for implant placement using mandibular bone grafts. *Implant Dent* 4:261, 1995
9. Jensen OT, Cockrell R, Kuhike L, et al: Anterior maxillary alveolar distraction osteogenesis: A prospective 5-year clinical study. *Int J Oral Maxillofac Implants* 17:52, 2002
10. Louis PJ, Gutta R, Said-Al-Naief N, et al: Reconstruction of the maxilla and mandible with particulate bone graft and titanium mesh for implant placement. *J Oral Maxillofac Surg* 66:235, 2008
11. Boyne PJ: Maxillofacial surgery, *in* Habal MB, Reddi AH (eds): *Bone Grafts and Bone Graft Substitutes*. Philadelphia, PA, W.B. Saunders, 1992, p 291
12. Thor A: Reconstruction of the anterior maxilla with platelet gel, autogenous bone and titanium mesh: A case report. *Clin Implant Dent Relat Res* 4:150, 2002
13. Simion M, Jovanovic SA, Tinti C, et al: Long-term evaluation of osseointegrated implants inserted at the same time or after vertical ridge augmentation: A retrospective study on 123 implants with 1-5 year follow-up. *Clin Oral Implants Res* 12:35, 2001
14. Fugazzotto PA: Report of 302 consecutive ridge augmentation procedures: Technical considerations and clinical results. *Int J Oral Maxillofac Implants* 13:358, 1998
15. Marx RE, Shellenberger T, Wimsatt J, et al: Severely resorbed mandible: Predictable reconstruction with soft tissue matrix expansion (tent pole) grafts. *J Oral Maxillofac Surg* 60:878, 2002

16. Block MS, Degen M: Horizontal ridge augmentation using human mineralized particulate bone: Preliminary results. *J Oral Maxillofac Surg* 62:67, 2004
17. Le B, Burstein J, Sedghizadeh PP: Cortical tenting grafting technique in the severely atrophic alveolar ridge for implant site preparation. *Implant Dent* 17:140, 2008
18. Le B, Burstein J: Esthetic grafting for small volume hard and soft tissue contour defects for implant site development. *Implant Dent* 17:136, 2008
19. James JD, Geist ET, Gross BD: Adynamic ileus as a complication of iliac bone removal: Report of two cases. *J Oral Surg* 39:289, 1981
20. Doblin JM, Salkin LM, Mellado JR, et al: A histologic evaluation of localized ridge augmentation utilizing DFDBA in combination with e-PTFE membranes and stainless steel bone pins in humans. *Int J Periodontics Restorative Dent* 16:120, 1996
21. Marx RE: Bone and bone grafting. *Oral Maxillofac Surg Clin North Am* 19:455, 2007
22. Gielkens PF, Bos RR, Raghoobar GM, et al: Is there evidence that barrier membranes prevent bone resorption in autologous bone grafts during the healing period? A systematic review. *Int J Oral Maxillofac Implants* 22:390, 2007
23. Wallace SS, Froum SJ: Effect of maxillary sinus augmentation on the survival of endosseous dental implants. A systematic review. *Ann Periodontol* 8:328, 2003
24. Wang HL, Boyapati L: "PASS" principles for predictable bone regeneration. *Implant Dent* 15:8, 2006
25. Tarnow DP, Wallace SS, Froum SJ, et al: Histologic and clinical comparison of bilateral sinus floor elevations with and without barrier membrane placement in 12 patients. Part 3 of an ongoing prospective study. *Int J Periodontics Restorative Dent* 20:116, 2000
26. Tawil G, Mawla M: Sinus floor elevation using a bovine bone mineral (Bio-Oss) with or without the concomitant use of a bilayered collagen barrier (bio-Gide): A clinical report of immediate and delayed implant placement. *Int J Oral Maxillofac Implants* 16:713, 2001
27. Froum SJ, Tarnow DP, Wallace SS, et al: Sinus floor elevation using anorganic bovine bone matrix (OsteoGraf/N) with and without autogenous bone: A clinical, histologic, radiographic, and histomorphometric analysis-Part 2 of an ongoing prospective study. *Int J Periodontics Restorative Dent* 8:529, 1998